

بِسْمِ اللَّهِ الرَّحْمَنِ الرَّحِيمِ

CDP for real-time intra-operative margin detection in Breast Cancer (**Electrotechnical Surgery**)

By: M.Abdolahad
(University of Tehran)



Bio electronics of tissue and cells

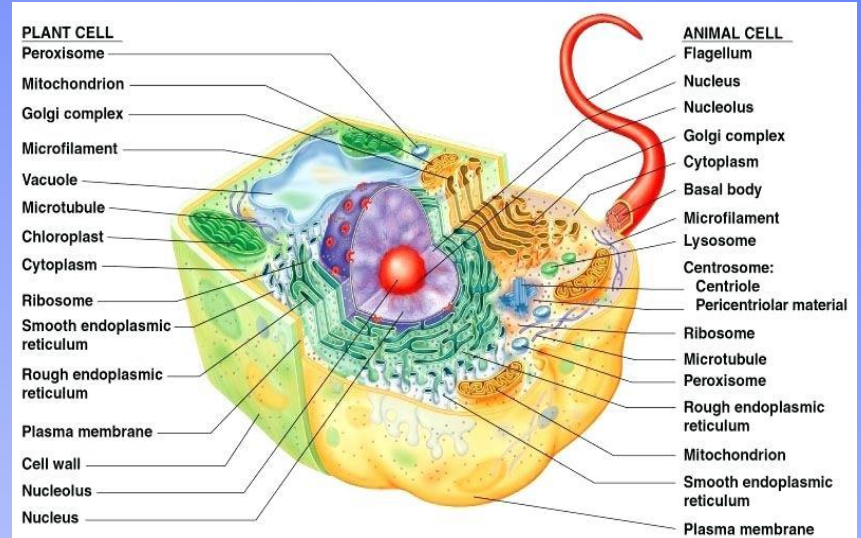
-Cells (Conductors and dielectrics)

➤ Properties (Cancer and normal)

- ✓ Membrane
- ✓ Cytoplasm

➤ Functions (Glycolysis, Mitosis, Invasion, Migration,...)

- ✓ Cell structure (Membrane Voltage and Intracellular signaling)
- ✓ Secretion (by Product of Hypoxia Glycolysis)



United States Patent of CDP



US 20180299401A1

(19) **United States**

(12) **Patent Application Publication**

Abdolahad et al.

(10) **Pub. No.: US 2018/0299401 A1**

(43) **Pub. Date: Oct. 18, 2018**

(54) **REAL-TIME AND LABEL FREE ANALYZER FOR IN-VITRO AND IN-VIVO DETECTING THE SUSPICIOUS REGIONS TO CANCER**

G01N 33/483 (2006.01)

A61B 5/1473 (2006.01)

A61B 5/00 (2006.01)

(71) Applicants: **Mohammad Abdolahad**, Tehran (IR);
Zohreh Sadat Miripour, Tehran (IR);
Sahar NajafiKhoshnoo, Tehran (IR)

(52) **U.S. Cl.**

CPC *G01N 27/3278* (2013.01); *G01N 27/3277* (2013.01); *G01N 27/48* (2013.01); *A61B 2562/046* (2013.01); *A61B 5/14735* (2013.01); *A61B 5/6849* (2013.01); *A61B 2562/0285* (2013.01); *G01N 33/4833* (2013.01)

(72) Inventors: **Mohammad Abdolahad**, Tehran (IR);
Zohreh Sadat Miripour, Tehran (IR);
Sahar NajafiKhoshnoo, Tehran (IR)

(21) Appl. No.: **16/010,510**


(22) Filed: **Jun. 17, 2018**

(57) **ABSTRACT**

Related U.S. Application Data

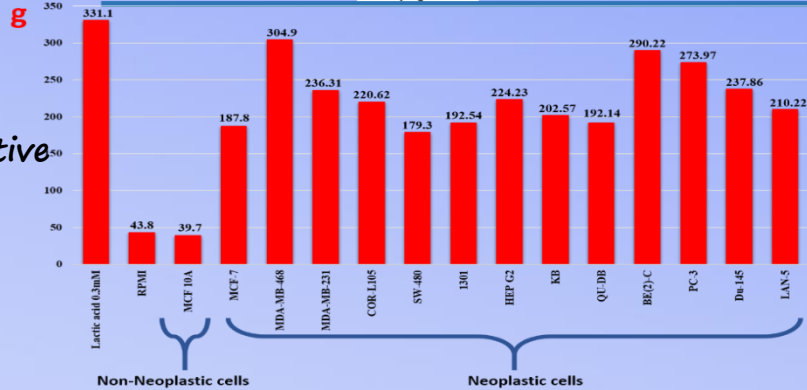
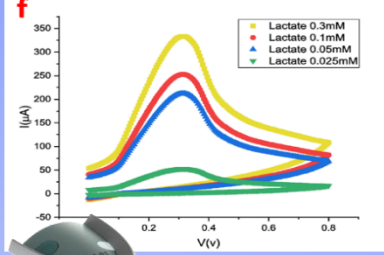
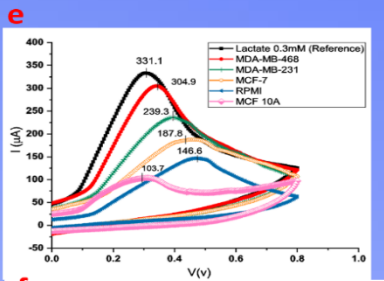
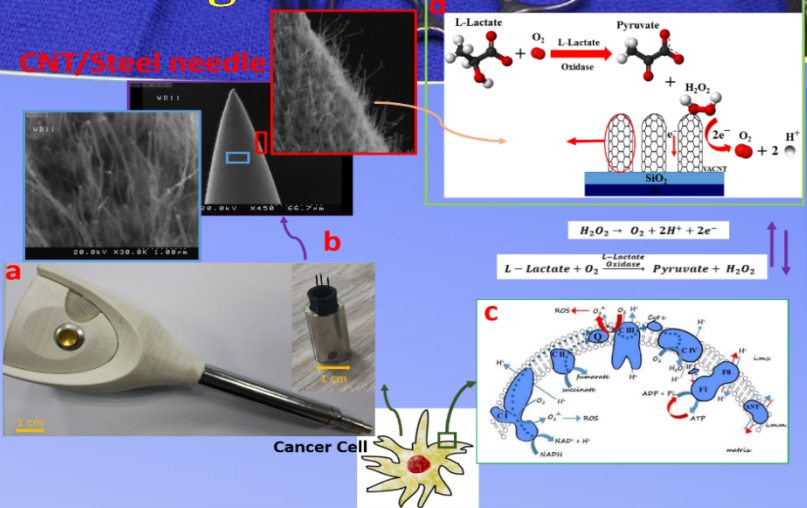
(60) Provisional application No. 62/522,115, filed on Jun. 20, 2017; provisional application No. 62/563,673

A label free method for cancer diagnosis is disclosed. The method includes putting an array of vertically aligned multi-walled carbon nanotubes (VAMWCNTs) of a sensor in



Real-time intra-operative *in-vivo* diagnosis of internal margins involved to breast cancer cells using a handheld electrochemical system

Hypoxia
Glycolysis

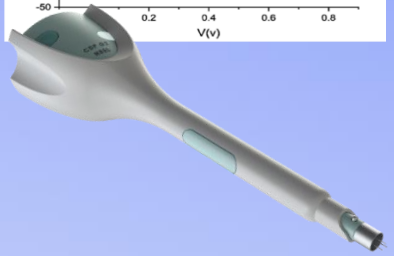


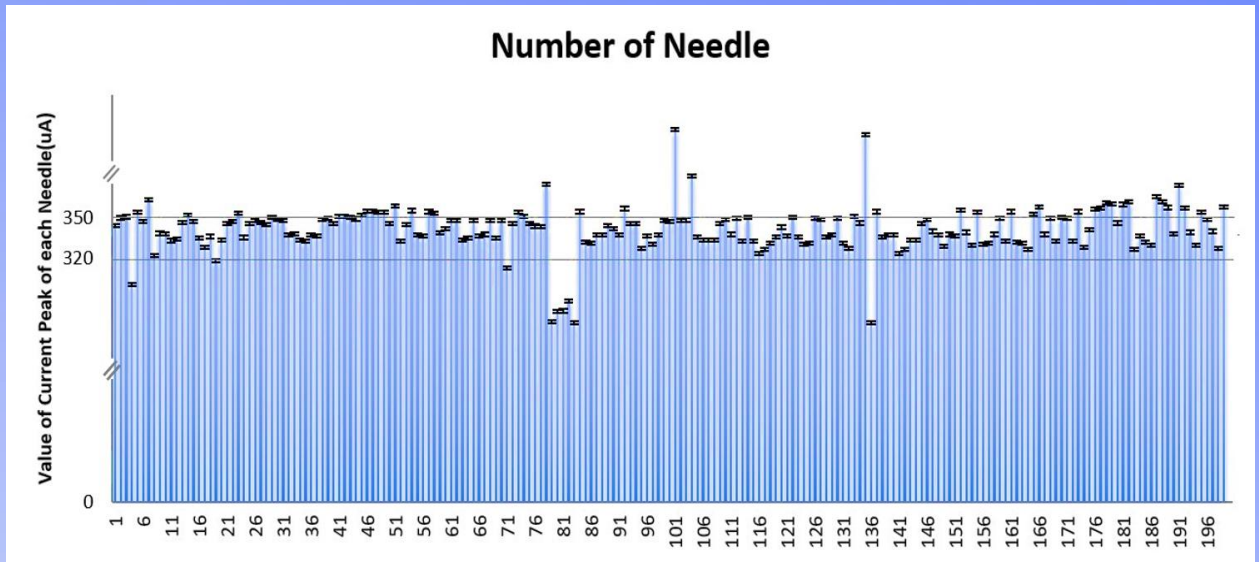
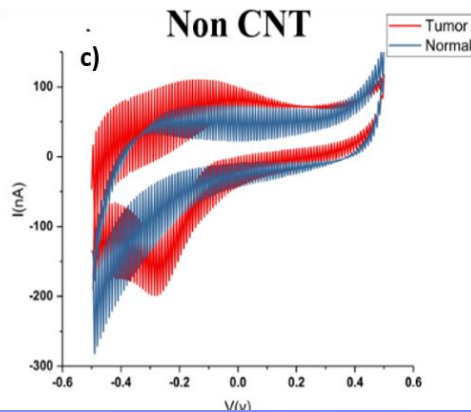
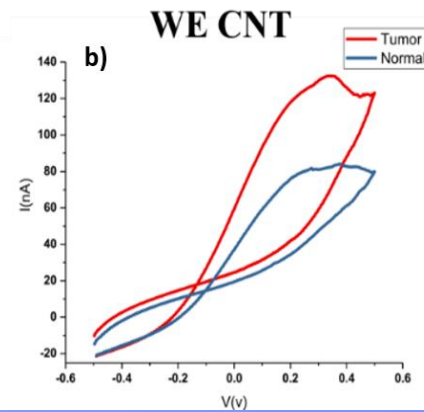
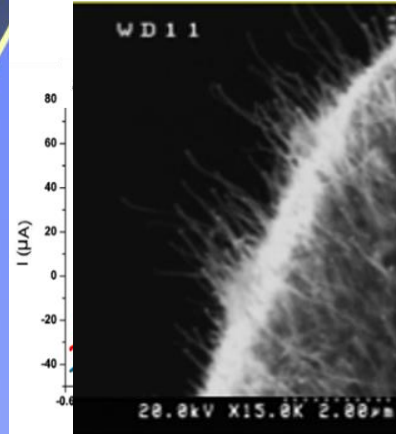
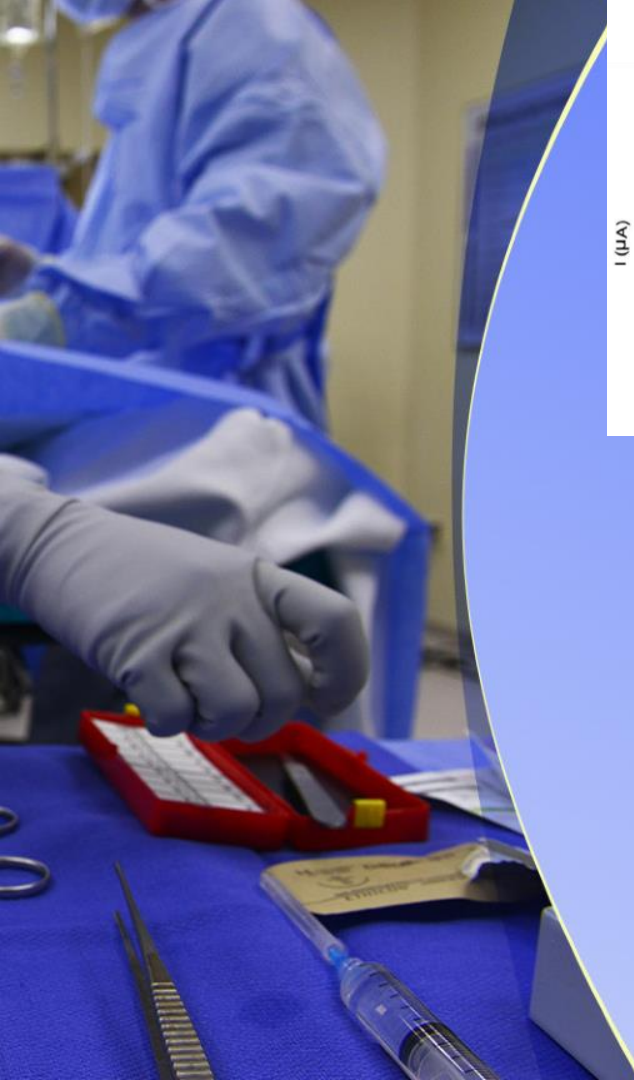1 Real-time

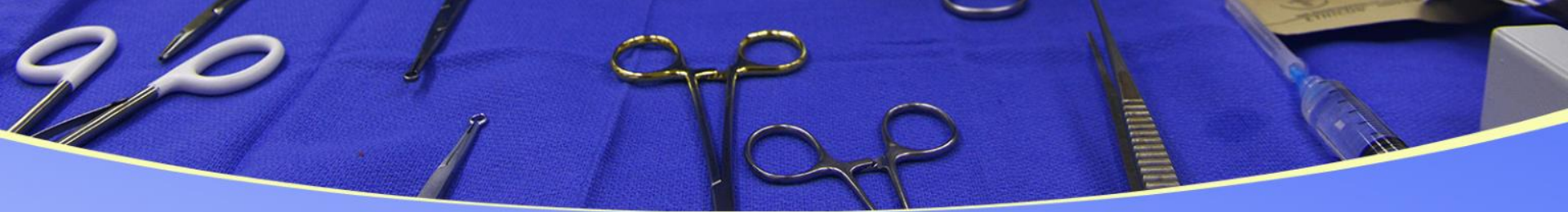2 Intra-operative

3 In-vivo

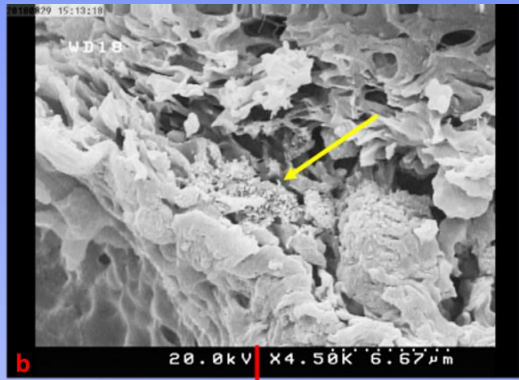



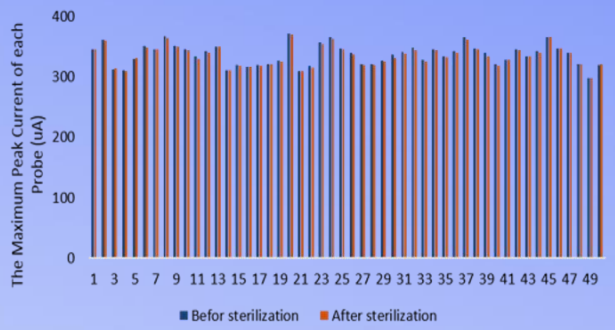
handheld electrochemical system (CDP)



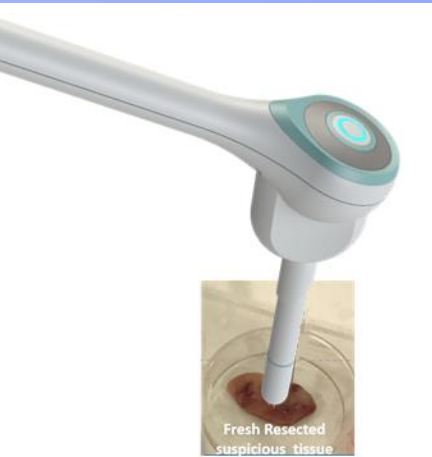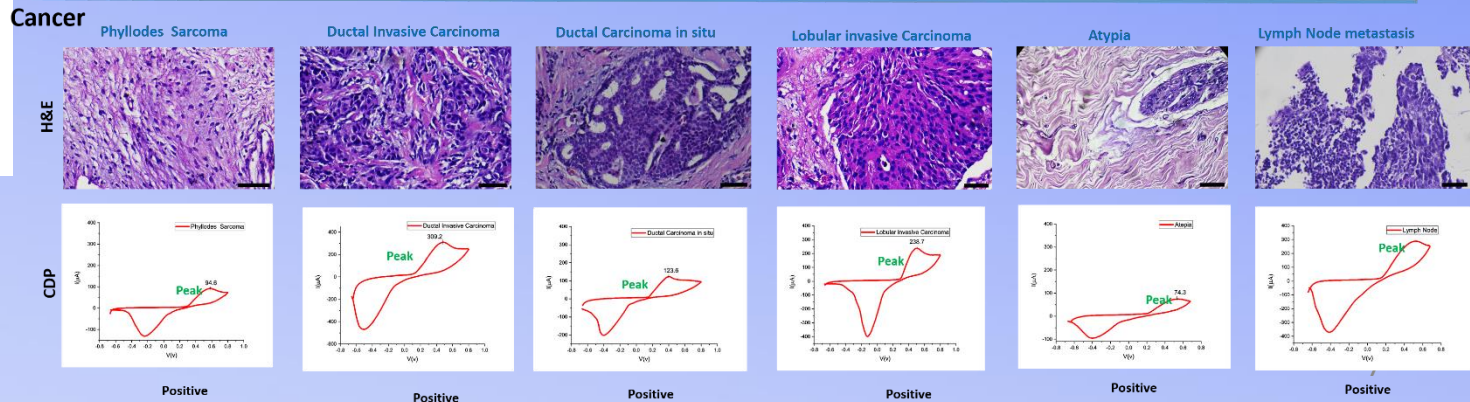
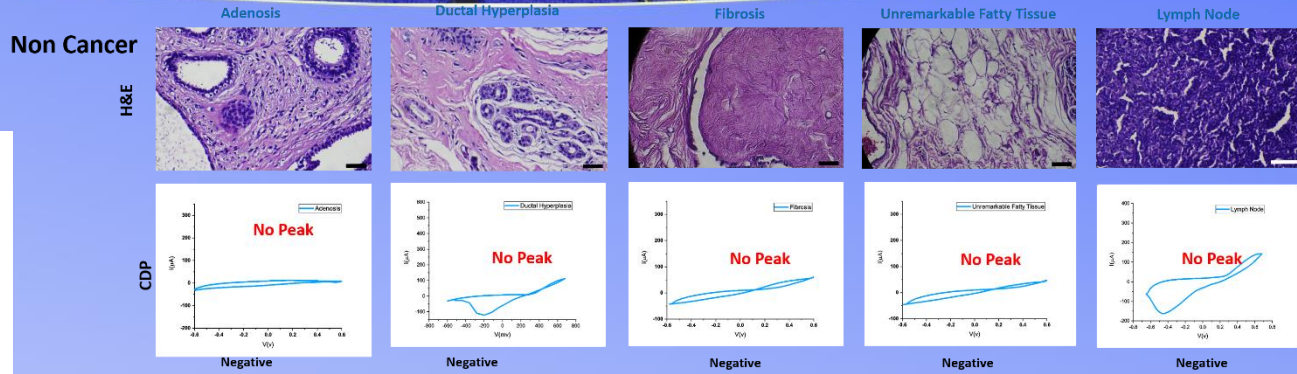




a) The Effect of Sterilization on CDP Probes



In-vitro (74 Human and Mice samples)





HIF-1 α

Table 2. Increased hypoxia-inducible factor-1 α (HIF-1 α) level in tissues at different stages during breast carcinogenesis

| | No. | HIF-1 α positivity,* No. | % HIF-1 α † | |
|---------------------------------|-----|---------------------------------|--------------------|-------|
| | | | Mean | Range |
| Normal breast tissue | 10 | 0 | 0 | 0–0 |
| Usual hyperplasia | 10 | 0 | 0 | 0–0 |
| DCIS, well differentiated‡ | 20 | 11 | 3.5 | 0–15 |
| DCIS,‡ poorly differentiated | 20 | 17 | 14.9 | 0–50 |
| Invasive, well differentiated | 20 | 12 | 11.8 | 0–53 |
| Invasive, poorly differentiated | 20 | 20 | 15.7 | 1–53 |

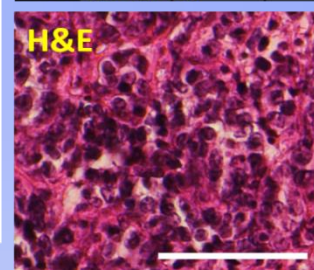
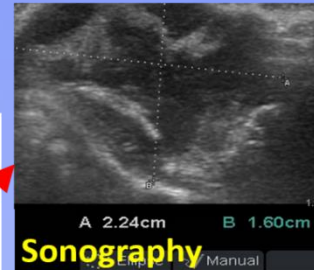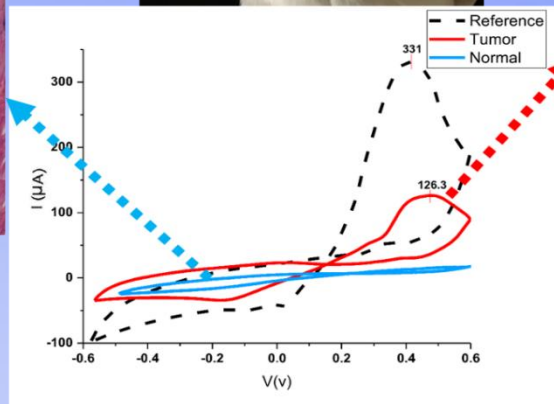
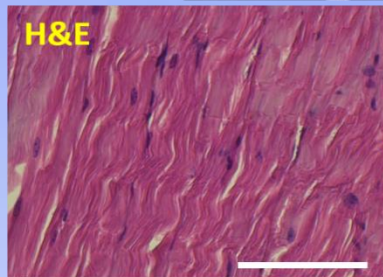
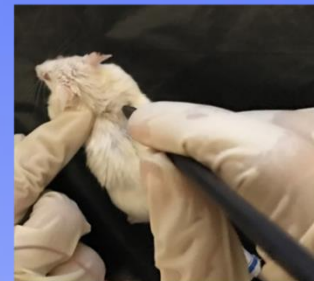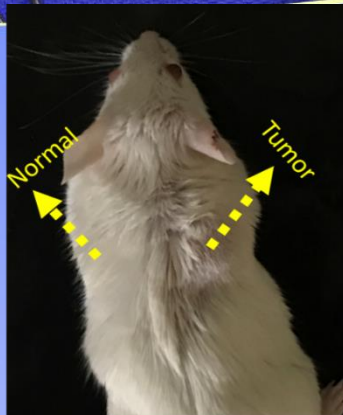
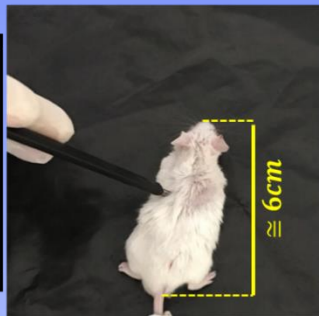
*HIF-1 α positivity = 1% or higher positive cells (per tissue sample).

†Mean percentage of positive cells (per tissue sample).


‡DCIS = ductal carcinoma *in situ*.

Mice's Model (*In-vitro* and *In-vivo* tests)

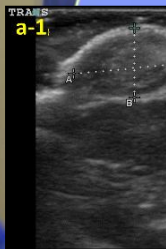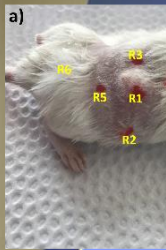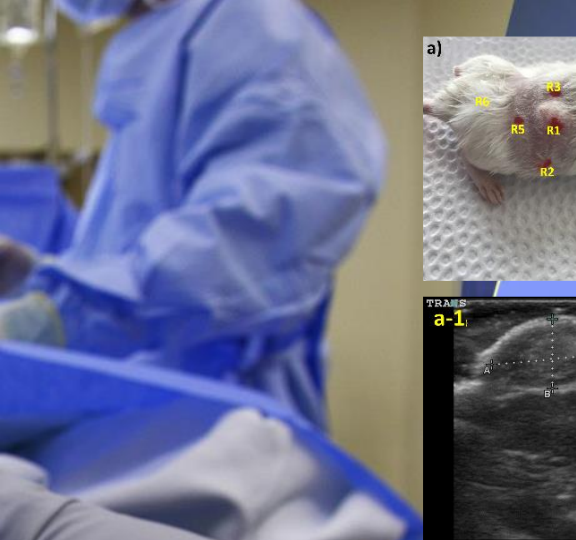
In-vivo analysis of observable tumor with histologically distinct cancer margin before any mastectomy



a) Head probe used in mice model tests



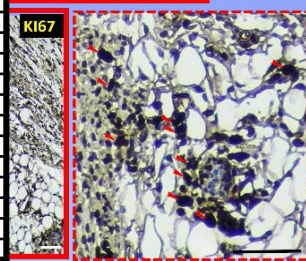
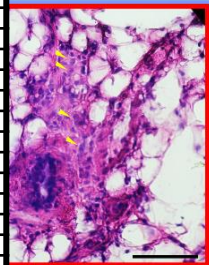
b) Head probe used in human model tests



In-vivo analysis of observable tumor with histologically distinct margin before and during surgery

| Mouse ID | CDP | | | | | | Frozen H&E | | | | | | Permanent H&E | | | | | |
|----------|-----|-----|-----|-----|-----|-----|------------|----|----|----|----|----|---------------|----|----|----|----|----|
| | R1 | R2 | R3 | R4 | R5 | R6 | R1 | R2 | R3 | R4 | R5 | R6 | R1 | R2 | R3 | R4 | R5 | R6 |
| 1 | POS | NEG | POS | NEG | NEG | NEG | ✓ | ✓ | ✓ | ✓ | ✓ | ✓ | ✓ | ✓ | ✓ | ✓ | ✓ | ✓ |
| 2 | POS | NEG | NEG | NEG | POS | NEG | ✓ | ✗ | ✗ | ✗ | ✗ | ✗ | ✓ | ✗ | ✗ | ✗ | ✗ | ✗ |
| 3 | POS | NEG | POS | NEG | POS | NEG | ✓ | ✗ | ✓ | ✗ | ✓ | ✗ | ✓ | ✗ | ✓ | ✗ | ✓ | ✗ |
| 4 | POS | NEG | POS | NEG | POS | NEG | ✓ | ✗ | ✗ | ✗ | ✗ | ✗ | ✓ | ✗ | ✗ | ✗ | ✓ | ✗ |
| 5 | POS | NEG | NEG | NEG | NEG | NEG | ✓ | ✗ | ✗ | ✗ | ✗ | ✗ | ✓ | ✗ | ✗ | ✗ | ✗ | ✗ |
| 6 | POS | NEG | POS | NEG | NEG | NEG | ✓ | ✗ | ✗ | ✗ | ✗ | ✗ | ✓ | ✗ | ✗ | ✗ | ✗ | ✗ |
| 7 | POS | NEG | NEG | NEG | POS | NEG | ✓ | ✗ | ✗ | ✗ | ✗ | ✗ | ✓ | ✗ | ✗ | ✗ | ✗ | ✗ |
| 8 | POS | POS | POS | NEG | NEG | NEG | ✓ | ✓ | ✓ | ✗ | ✗ | ✗ | ✓ | ✗ | ✗ | ✗ | ✗ | ✗ |
| 9 | POS | NEG | NEG | NEG | POS | NEG | ✓ | ✗ | ✗ | ✗ | ✗ | ✗ | ✓ | ✗ | ✗ | ✗ | ✗ | ✗ |
| 10 | POS | NEG | POS | NEG | POS | NEG | ✓ | ✗ | ✗ | ✗ | ✗ | ✗ | ✓ | ✗ | ✗ | ✗ | ✗ | ✗ |
| 11 | POS | NEG | NEG | POS | POS | NEG | ✓ | ✗ | ✗ | ✗ | ✓ | ✗ | ✓ | ✗ | ✗ | ✗ | ✗ | ✗ |
| 12 | POS | POS | NEG | NEG | POS | NEG | ✓ | ✓ | ✗ | ✗ | ✗ | ✗ | ✓ | ✗ | ✗ | ✗ | ✓ | ✗ |
| 13 | POS | POS | POS | NEG | POS | NEG | ✓ | ✓ | ✓ | ✗ | ✓ | ✗ | ✓ | ✓ | ✗ | ✗ | ✓ | ✗ |
| 14 | POS | NEG | POS | NEG | NEG | NEG | ✓ | ✗ | ✓ | ✗ | ✗ | ✗ | ✓ | ✗ | ✗ | ✗ | ✗ | ✗ |
| 15 | POS | POS | POS | NEG | NEG | NEG | ✓ | ✓ | ✓ | ✗ | ✗ | ✗ | ✓ | ✓ | ✗ | ✗ | ✗ | ✗ |
| 16 | POS | NEG | NEG | NEG | NEG | NEG | ✓ | ✗ | ✗ | ✗ | ✗ | ✗ | ✓ | ✗ | ✗ | ✗ | ✗ | ✗ |
| 17 | POS | NEG | NEG | POS | NEG | NEG | ✓ | ✗ | ✗ | ✗ | ✗ | ✗ | ✓ | ✗ | ✗ | ✗ | ✗ | ✗ |
| 18 | POS | NEG | POS | NEG | POS | NEG | ✓ | ✗ | ✓ | ✓ | ✗ | ✗ | ✓ | ✗ | ✗ | ✗ | ✗ | ✗ |
| 19 | POS | POS | NEG | NEG | NEG | NEG | ✓ | ✓ | ✗ | ✗ | ✗ | ✗ | ✓ | ✓ | ✗ | ✗ | ✗ | ✗ |
| 20 | POS | POS | NEG | NEG | POS | NEG | ✓ | ✓ | ✗ | ✗ | ✗ | ✗ | ✓ | ✗ | ✗ | ✗ | ✗ | ✗ |
| 21 | POS | NEG | POS | NEG | NEG | NEG | ✓ | ✗ | ✗ | ✗ | ✗ | ✗ | ✓ | ✗ | ✗ | ✗ | ✗ | ✗ |
| 22 | POS | POS | NEG | POS | NEG | NEG | ✓ | ✓ | ✗ | ✓ | ✗ | ✗ | ✓ | ✓ | ✗ | ✗ | ✗ | ✗ |
| 23 | POS | NEG | NEG | POS | NEG | NEG | ✓ | ✗ | ✗ | ✗ | ✗ | ✗ | ✓ | ✗ | ✗ | ✗ | ✗ | ✗ |
| 24 | POS | NEG | POS | NEG | POS | NEG | ✓ | ✗ | ✗ | ✗ | ✗ | ✗ | ✓ | ✗ | ✗ | ✗ | ✗ | ✗ |
| 25 | POS | NEG | NEG | NEG | POS | NEG | ✓ | ✗ | ✗ | ✗ | ✓ | ✗ | ✓ | ✗ | ✗ | ✗ | ✗ | ✗ |
| 26 | POS | NEG | POS | POS | NEG | NEG | ✓ | ✗ | ✓ | ✓ | ✗ | ✗ | ✓ | ✗ | ✗ | ✗ | ✗ | ✗ |
| 27 | POS | NEG | NEG | POS | POS | NEG | ✓ | ✗ | ✗ | ✗ | ✗ | ✗ | ✓ | ✗ | ✗ | ✗ | ✗ | ✗ |
| 28 | POS | POS | NEG | NEG | NEG | NEG | ✓ | ✓ | ✗ | ✗ | ✗ | ✗ | ✓ | ✗ | ✗ | ✗ | ✗ | ✗ |
| 29 | POS | POS | POS | NEG | NEG | NEG | ✓ | ✓ | ✓ | ✗ | ✗ | ✗ | ✓ | ✗ | ✗ | ✗ | ✗ | ✗ |
| 30 | POS | NEG | POS | NEG | POS | NEG | ✓ | ✗ | ✓ | ✗ | ✗ | ✗ | ✓ | ✗ | ✓ | ✗ | ✗ | ✗ |
| 31 | POS | NEG | NEG | POS | NEG | NEG | ✓ | ✗ | ✗ | ✗ | ✗ | ✗ | ✓ | ✗ | ✗ | ✗ | ✗ | ✗ |
| 32 | POS | NEG | POS | POS | NEG | NEG | ✓ | ✗ | ✓ | ✓ | ✗ | ✗ | ✓ | ✗ | ✓ | ✓ | ✗ | ✗ |
| 33 | POS | NEG | NEG | NEG | POS | NEG | ✓ | ✗ | ✗ | ✗ | ✓ | ✗ | ✓ | ✗ | ✗ | ✗ | ✗ | ✗ |
| 34 | POS | NEG | POS | NEG | NEG | NEG | ✓ | ✗ | ✗ | ✗ | ✗ | ✗ | ✓ | ✗ | ✗ | ✗ | ✗ | ✗ |
| 35 | POS | NEG | POS | NEG | NEG | NEG | ✓ | ✗ | ✓ | ✗ | ✗ | ✗ | ✓ | ✗ | ✗ | ✗ | ✗ | ✗ |
| 36 | POS | POS | NEG | NEG | POS | NEG | ✓ | ✓ | ✗ | ✗ | ✓ | ✗ | ✓ | ✓ | ✗ | ✗ | ✗ | ✗ |
| 37 | POS | POS | NEG | NEG | NEG | NEG | ✓ | ✓ | ✓ | ✗ | ✗ | ✗ | ✓ | ✗ | ✗ | ✗ | ✗ | ✗ |
| 38 | POS | POS | NEG | POS | NEG | NEG | ✓ | ✓ | ✗ | ✗ | ✗ | ✗ | ✓ | ✗ | ✗ | ✗ | ✗ | ✗ |
| 39 | POS | NEG | POS | NEG | NEG | NEG | ✓ | ✗ | ✓ | ✗ | ✗ | ✗ | ✓ | ✗ | ✓ | ✗ | ✗ | ✗ |
| 40 | POS | NEG | POS | NEG | POS | NEG | ✓ | ✗ | ✓ | ✗ | ✗ | ✗ | ✓ | ✗ | ✗ | ✗ | ✗ | ✗ |
| 41 | POS | POS | NEG | POS | NEG | NEG | ✓ | ✓ | ✗ | ✗ | ✓ | ✗ | ✓ | ✗ | ✗ | ✗ | ✗ | ✗ |
| 42 | POS | NEG | NEG | POS | POS | NEG | ✓ | ✗ | ✗ | ✓ | ✓ | ✗ | ✓ | ✗ | ✗ | ✗ | ✗ | ✗ |
| 43 | POS | POS | POS | NEG | NEG | NEG | ✓ | ✓ | ✓ | ✗ | ✗ | ✗ | ✓ | ✗ | ✗ | ✗ | ✗ | ✗ |
| 44 | POS | NEG | POS | POS | NEG | NEG | ✓ | ✗ | ✓ | ✓ | ✗ | ✗ | ✓ | ✗ | ✗ | ✗ | ✗ | ✗ |
| 45 | POS | POS | NEG | NEG | POS | NEG | ✓ | ✓ | ✗ | ✗ | ✓ | ✗ | ✓ | ✓ | ✗ | ✗ | ✗ | ✗ |
| 46 | POS | POS | POS | NEG | NEG | NEG | ✓ | ✓ | ✓ | ✗ | ✗ | ✗ | ✓ | ✓ | ✗ | ✗ | ✗ | ✗ |
| 47 | POS | POS | POS | POS | NEG | NEG | ✓ | ✓ | ✓ | ✓ | ✗ | ✗ | ✓ | ✓ | ✓ | ✗ | ✗ | ✗ |
| 48 | POS | POS | NEG | POS | NEG | NEG | ✓ | ✓ | ✗ | ✓ | ✗ | ✗ | ✓ | ✗ | ✗ | ✗ | ✗ | ✗ |
| 49 | POS | NEG | POS | NEG | NEG | NEG | ✓ | ✗ | ✗ | ✓ | ✗ | ✗ | ✓ | ✗ | ✗ | ✗ | ✗ | ✗ |
| 50 | POS | NEG | NEG | POS | POS | NEG | ✓ | ✗ | ✗ | ✓ | ✓ | ✗ | ✓ | ✗ | ✗ | ✗ | ✗ | ✗ |

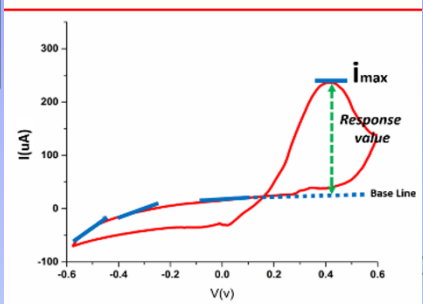
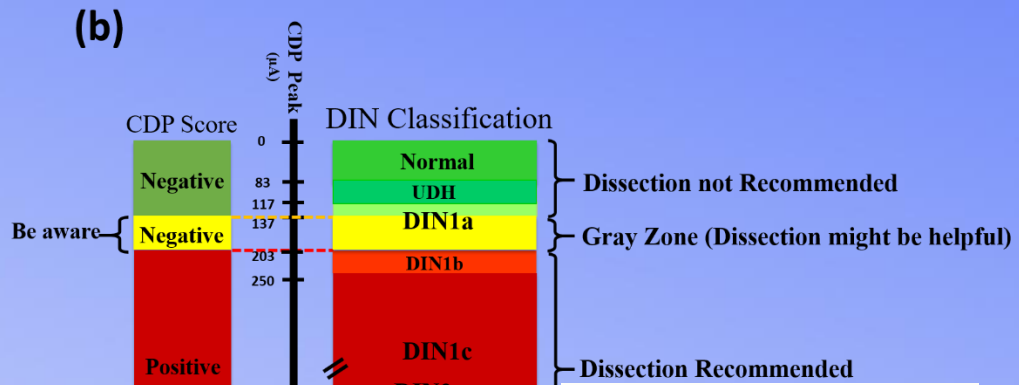
| CDP During Surgery (μA) | H&E Frozen (Cancer) |
|-------------------------|---------------------|
| 420 (+) | Yes |
| 280 (+) | Yes |
| 241 (+) | Yes |
| 110 (-) | No |
| 89 (-) | No |
| 11 (-) | No |



Response scoring based on WHO classification on Breast tumor disease

(a)

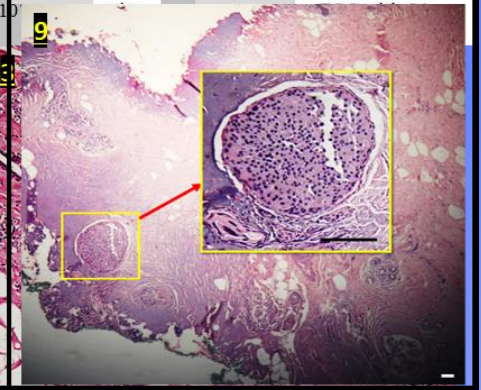
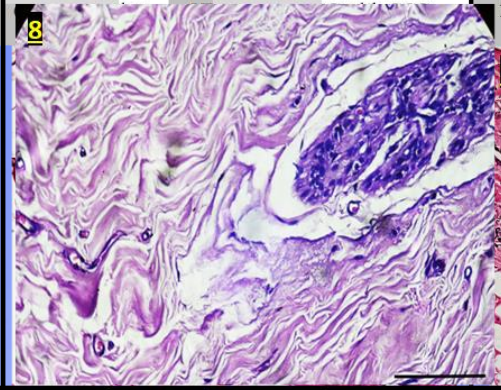
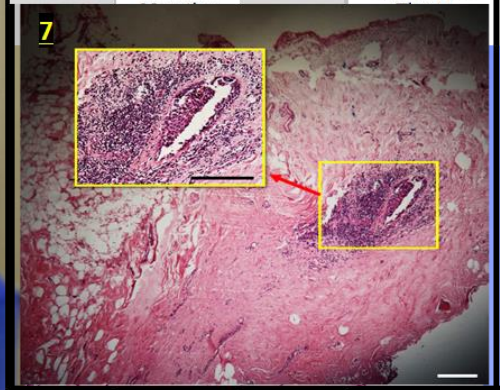
| Pathological Diagnosis | |
|--------------------------------|--|
| DIN categorization | Traditional terminology |
| Free | Normal breast and fatty tissues |
| Usual ductal hyperplasia (UDH) | Epitheliosis |
| | Infiltrating epitheliosis |
| | Papillomatosis |
| | Sclerosing adenosis with pseudoinfiltration |
| | Sclerosing papillary proliferation |
| DIN1a | Mild usual ductal hyperplasia |
| | Fibrocystic change with columnar cell change |
| | Clinging carcinoma monomorphous or type 2 |
| | Flat epithelial atypia |
| | Atypical cystic lobules |
| | Atypical lobules type A |
| | Atypical columnar change |
| | Moderate usual ductal hyperplasia |
| | Small of flat atypical |
| | Florid ductal hyperplasia |
| Papilloma | |
| DIN1b | Complex Fibroadenoma |
| DIN1b | Atypical ductal hyperplasia (ADH) |
| DIN1c | Low-grade ductal carcinoma in situ (LG-DCIS) |
| | DCIS grade 1 |
| DIN2 | Intermediate-grade ductal carcinoma in situ (IG-DCIS) DCIS grade 2 |
| DIN3 | High-grade ductal carcinoma in situ (HG-DCIS) DCIS grade 3 |



| CDP Response | | DIN based Diagnosis | |
|-------------------|----------------------|---------------------|-------------------------------------|
| Peak Current (μA) | Score for Dissection | DIN grading | Histological Diagnosis |
| 200 | Positive | DIN1a | FCC with a foci of Florid Fatty ADH |

| | | | |
|-----|----------|-------|-----|
| 224 | Positive | DIN1b | ADH |
|-----|----------|-------|-----|



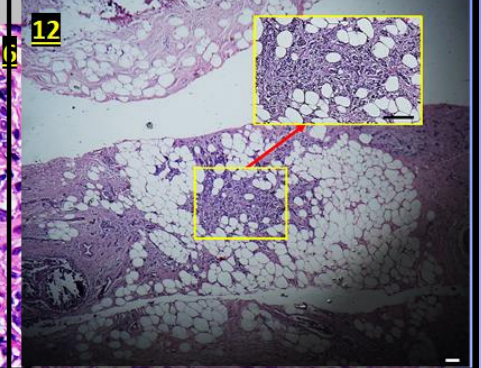
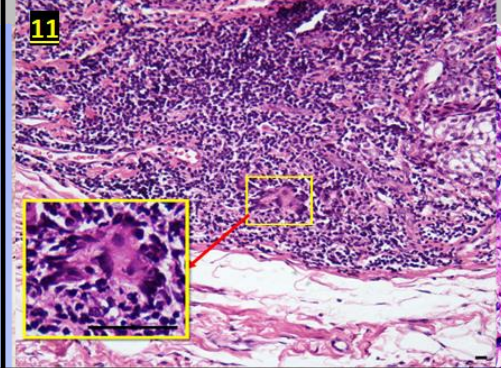
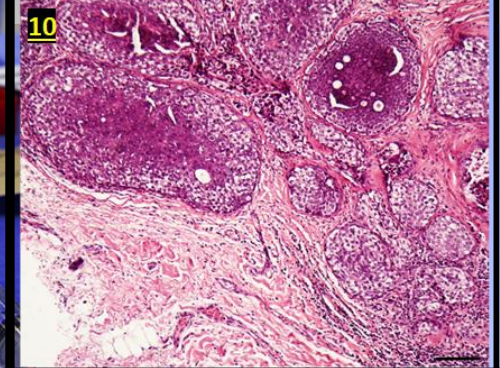
| | | | |
|-----|----------|-------|-----------------|
| 231 | Positive | DIN1c | A focus of DCIS |
|-----|----------|-------|-----------------|



| | | | |
|-----|----------------------|-------|------------------------------|
| 255 | Positive Negative | DIN1c | FCC with Moderate Typical DH |
|-----|----------------------|-------|------------------------------|

| | | | |
|-----|----------------------|-------|--|
| 262 | Positive Negative | DIN1c | Micro-Invasion CC with Florid typical DH |
|-----|----------------------|-------|--|

| | | | |
|-----|----------------------|------|------------------------------------|
| 288 | Positive Negative | ---- | IDC (> 5%) in Complex Fibroadenoma |
|-----|----------------------|------|------------------------------------|



Clinical study (Breast Surgery)



Two Guide lines :

1. Suspicious Regions to surgeon

2. Full scan (6 to 8 points for each margin)

5. Negative margin

1. Negative margin

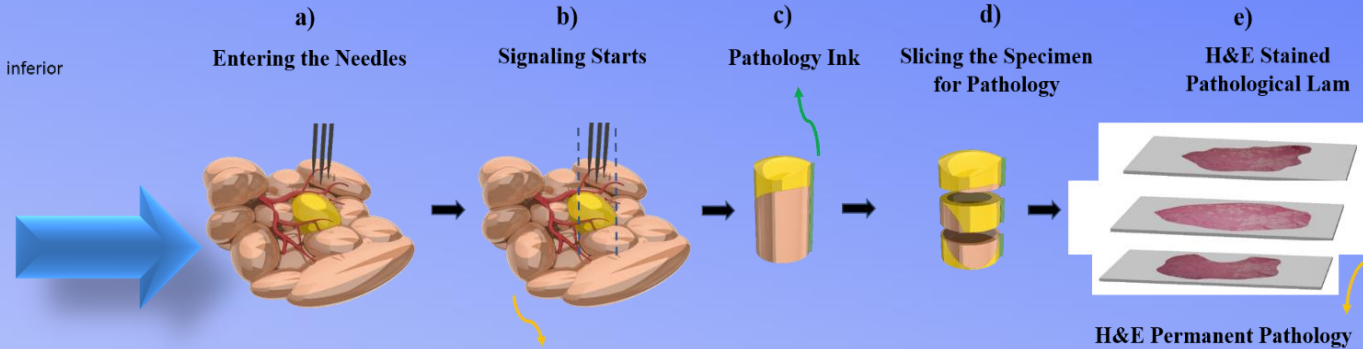
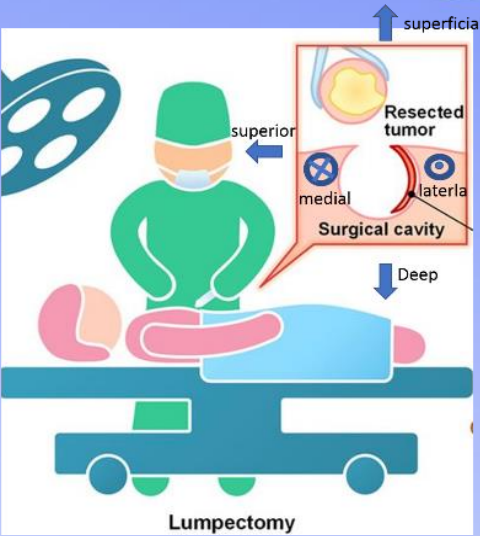
2. Positive margin: DCIS

3. Negative margin

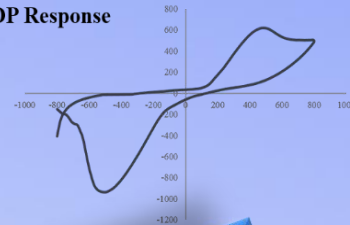
4. Negative margin

4 mm Needle
Stopper specimen

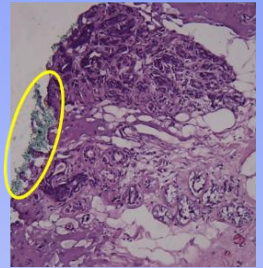
Clinical study (Test Protocol)




CDP Response



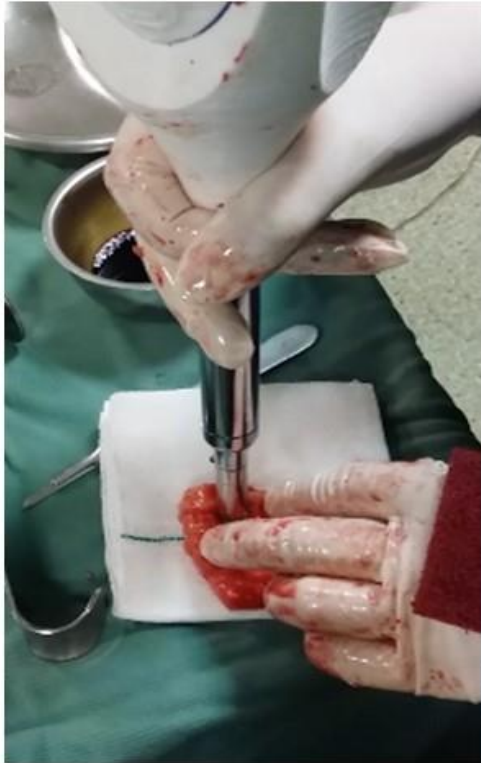Traces of Pathology Ink During Surgery



Preparation Setup of CDP

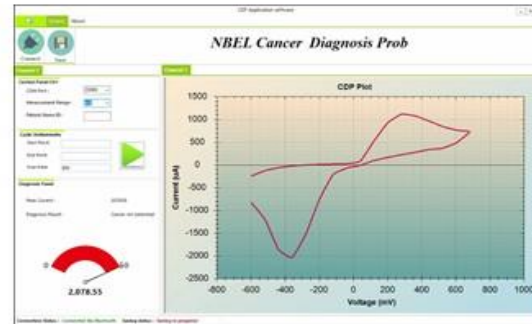


Clinical Study-Tumor

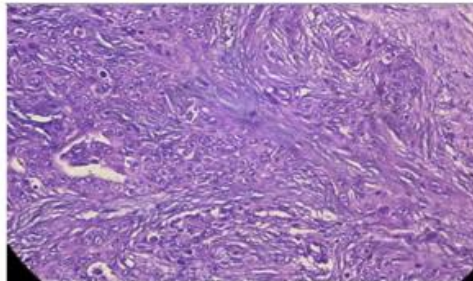


Tumor

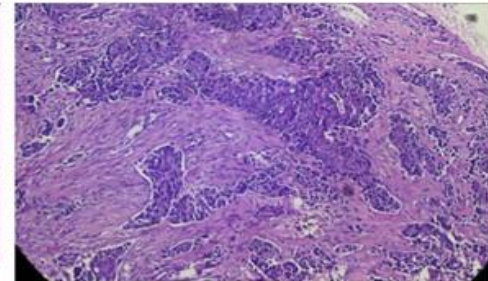
CDP Positive




Frozen Pathology Positive



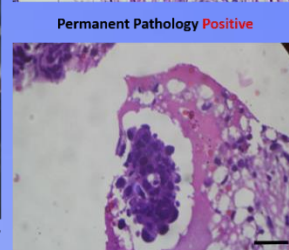
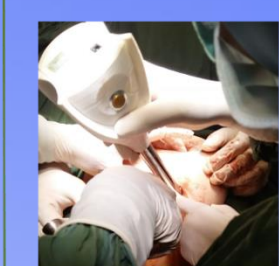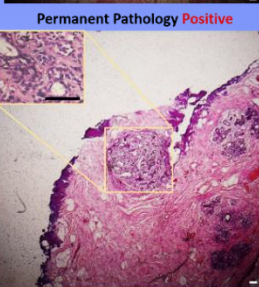
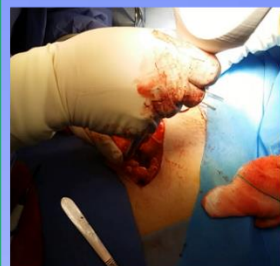
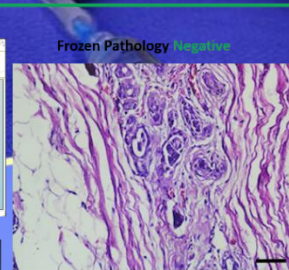
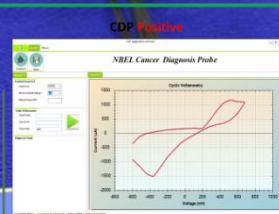
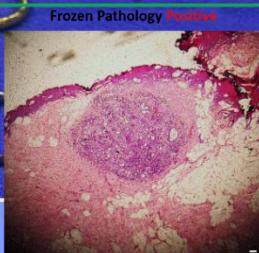
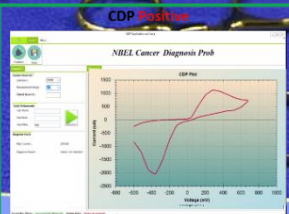
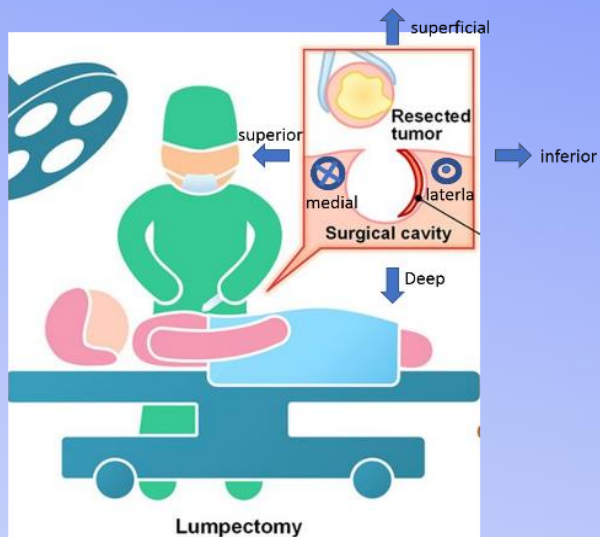
Permanent Pathology Positive



Clinical Study- Ex Vivo

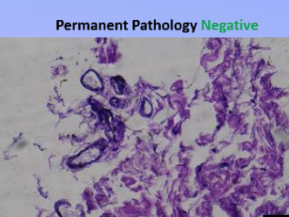
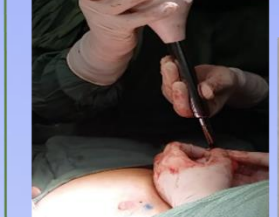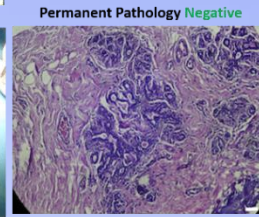
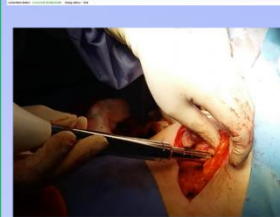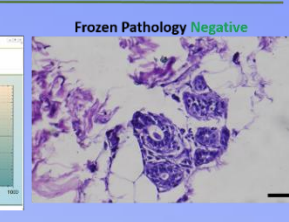
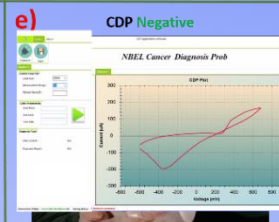
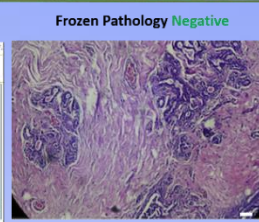
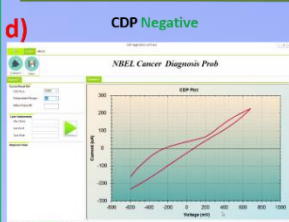


Clinical Study-Suspicious body side Margin



Suspicious Margin Inside the Body

Suspicious Margin Inside the Body

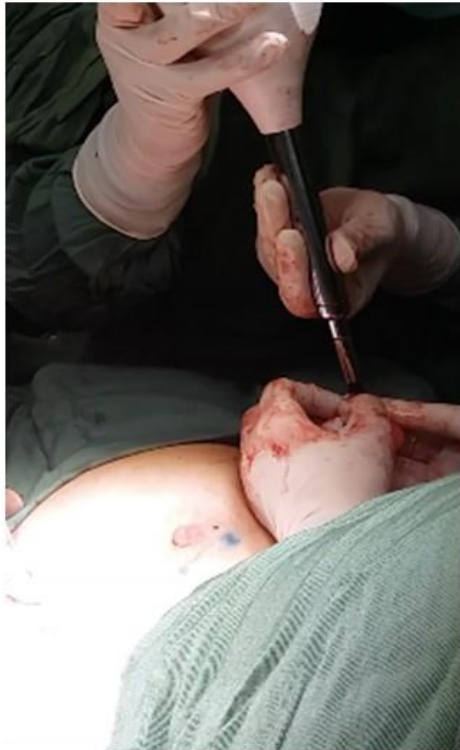

Suspicious margin inside the body

Lymph Node

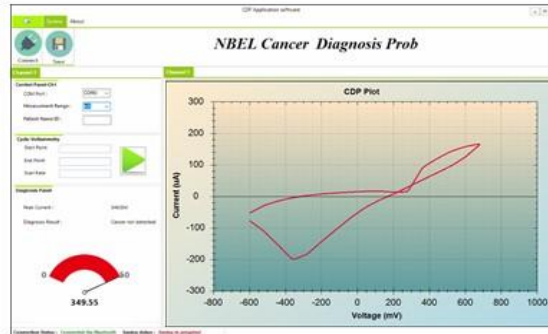
Clinical Study- In Vivo

Clinical Study-Lymph Node

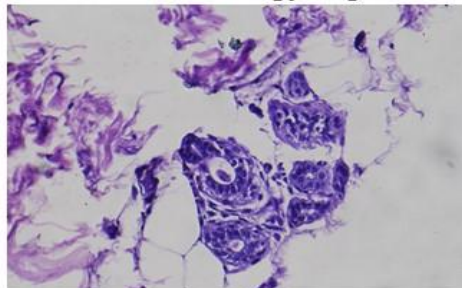


Lymph Node

CDP Negative for Lymph Node



Frozen Pathology Negative



Permanent Pathology Negative

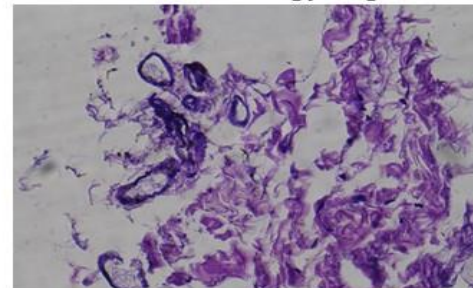
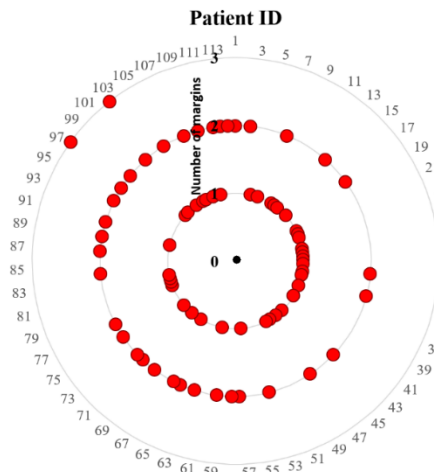


Table3. Investigation of Margins in 113 Patients with Breast Cancer by CDP During Surgery, Frozen H&E, and IHC (if required)

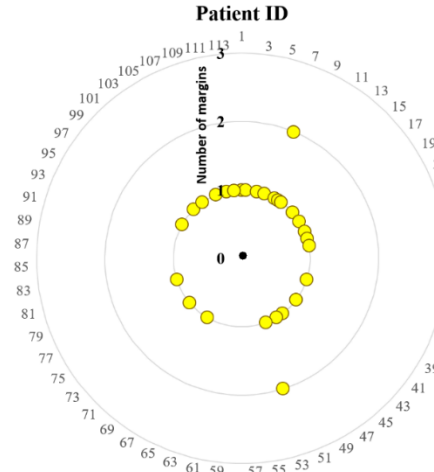
a)

Triple Positive
CDP +
Frozen +
Permanent +



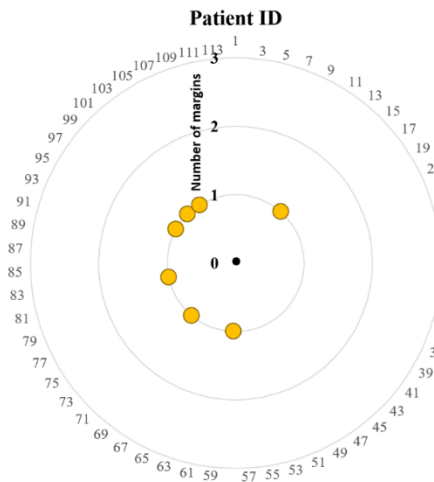
b)

Double Positive
CDP +
Frozen -
Permanent +



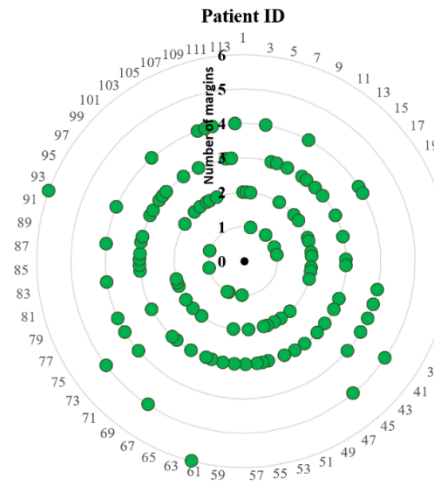
c)

Single Positive
CDP +
Frozen -
Permanent -
IHC +



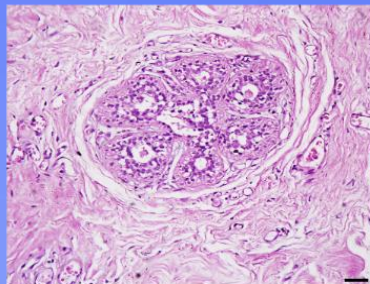
d)

Triple Negative
CDP -
Frozen -
Permanent -

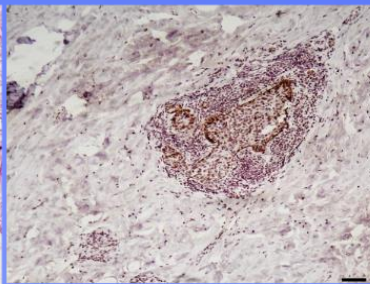


IHC in Discrepancies

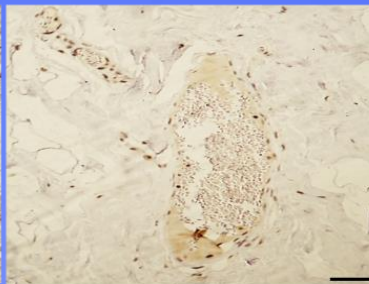
Suspicious benign (non-atypical DH) samples positively scored by CDP (CDP scoring were confirmed by IHC)



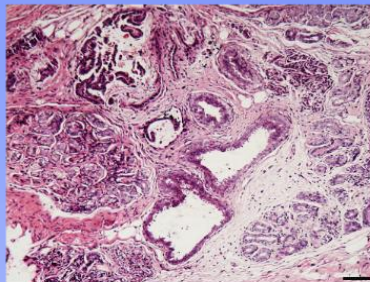
a) H&E Diagnosis: FCC with Florid ductal hyperplasia (Suspicious)



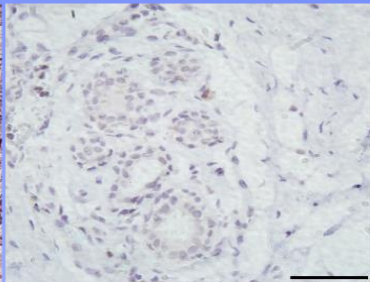
IHC: CK5/6 Negative (Atypia is confirmed)



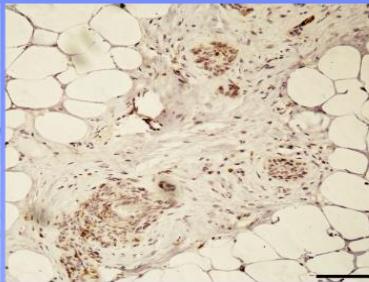
IHC: CK14 Negative (Atypia is confirmed)



b) H&E Diagnosis: FCC with columnar cell change (Suspicious)



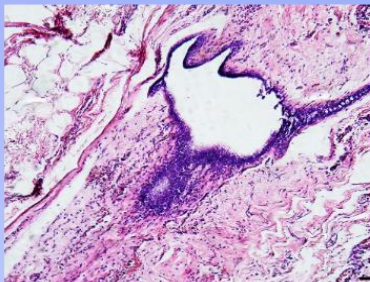
IHC: CK5/6 Negative (Atypia is confirmed)



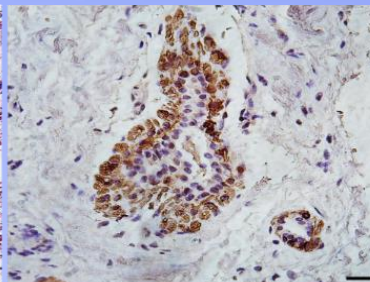
IHC: CK14 Negative (Atypia is confirmed)

Figure. **Suspicious Permanent** H&E of a) FCC with florid DH (Patient ID 15) and b) FCC with CCC (Patient ID 96) in which atypia was confirmed by IHC (CK 5/6, 14) staining. Hence, positive scoring of CDP was corroborated. Suspicious permanent H&E of c) Florid DH (Patient ID 95) in which atypia was rolled out by IHC. Hence CDP scoring was rejected.

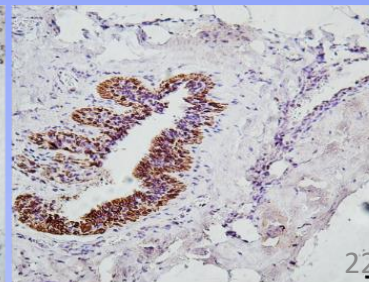
Suspicious benign (Florid DH) sample positively scored by CDP (Permanent H&E was confirmed by IHC)



c) H&E Diagnosis: Florid DH



IHC: CK 5/6 Positive (Atypia is rolled out)

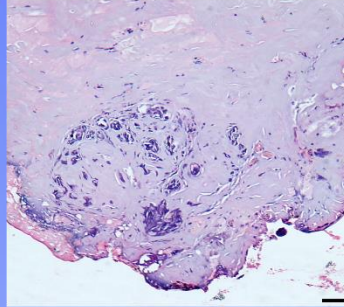


IHC: CK 14 Positive (Atypia is rolled out)

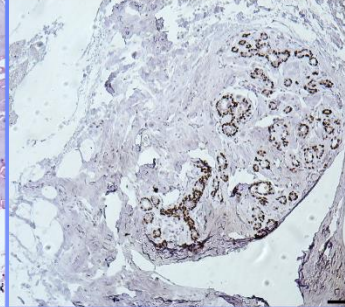
True Positive CDP

False Positive CDP

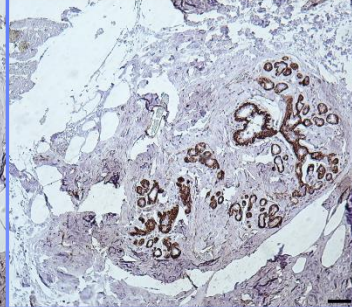
Samples negatively scored by CDP



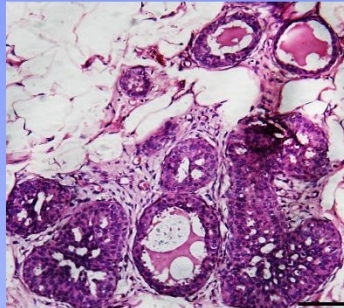
H&E permanent: FCC with SA



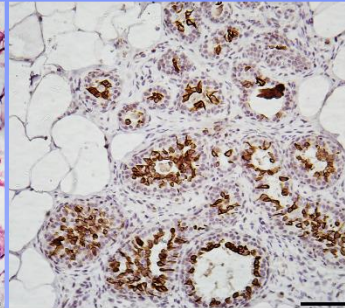
IHC: P63 Positive (Invasion is rolled out)



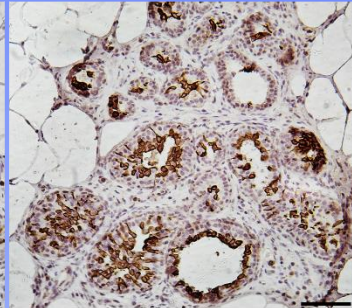
IHC: SMMH Positive (Invasion is rolled out)



H&E permanent: Florid DH

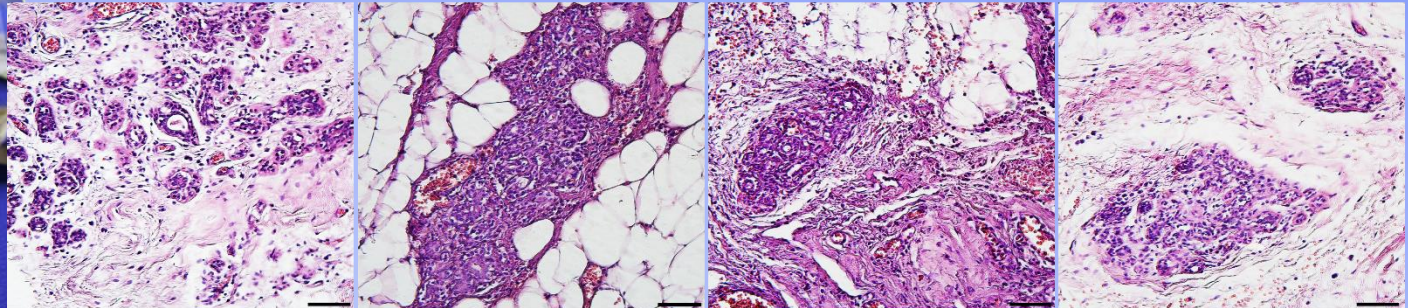


IHC: CK 5/6 Positive (Atypia is rolled out)



IHC: CK 14 Positive (Atypia is rolled out)

Triple negative

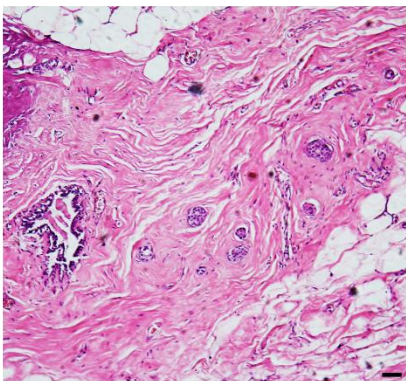


multilevel permanent H&E

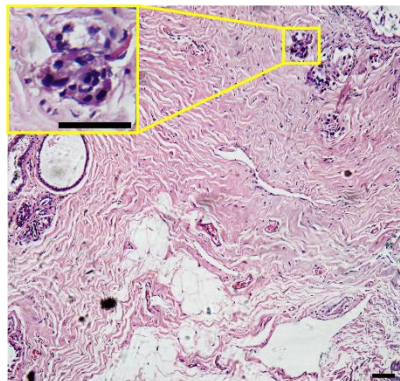
False Negative

High value False Negative (-/+/+)

a) Samples negatively scored by CDP (Green Zone)



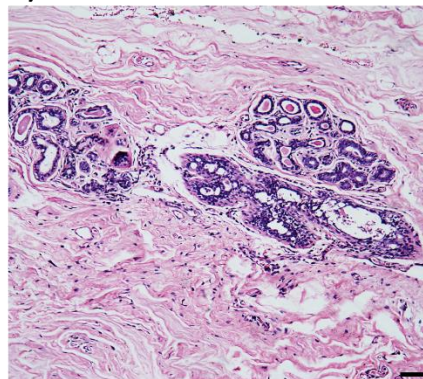
Frozen Pathology: Small foci of Invasive Carcinoma



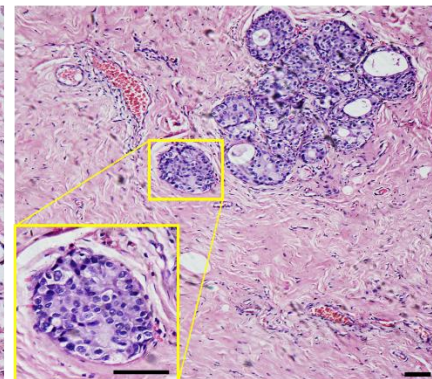
Permanent Pathology: IDC

Low value False Negative (-/-/+)

b) Samples negatively scored by CDP (Gray Zone)



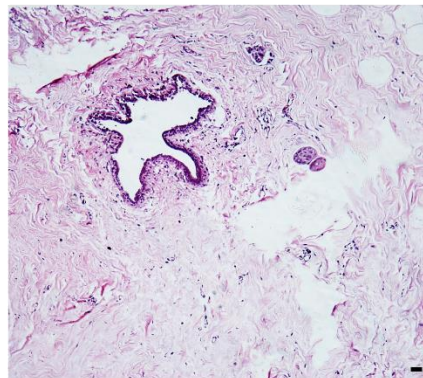
Frozen Pathology: FCC with hyperplasia



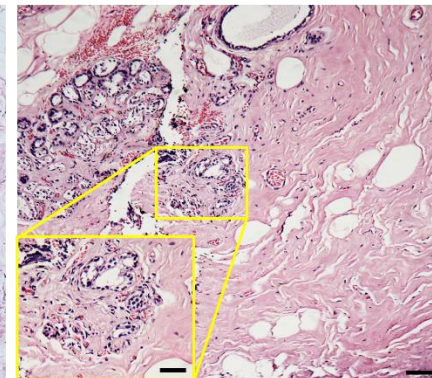
Permanent Pathology: DCIS

Low value False Negative (-/+/+)

c) Samples negatively scored by CDP (Gray Zone)



Frozen Pathology: Small foci of Invasive Carcinoma



Permanent Pathology: IDC

False
Negative

Blind Clinical trial

DIAGNOSIS:

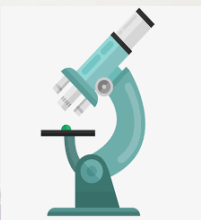A(2):Ductal intraepithelial neoplasia(DIN2)

-Microcalcification are also seen

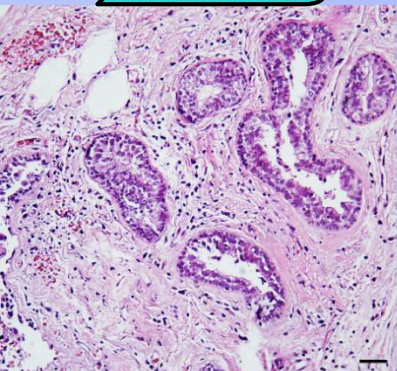
B(5):A small focus of invasive carcinoma in area is seen

-Other area show fibrocystic change with sclerosing adenosis

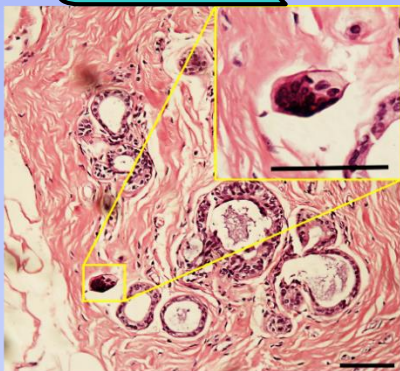
C(6):A small focus of invasive carcinoma in ink area is seen



Two EMs missed by frozen and permanent but detected IMs by CDP



(a)

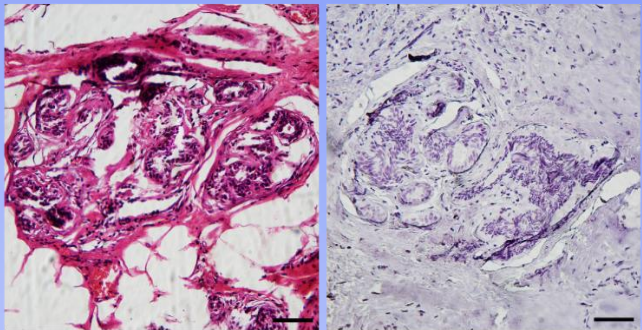


(b)

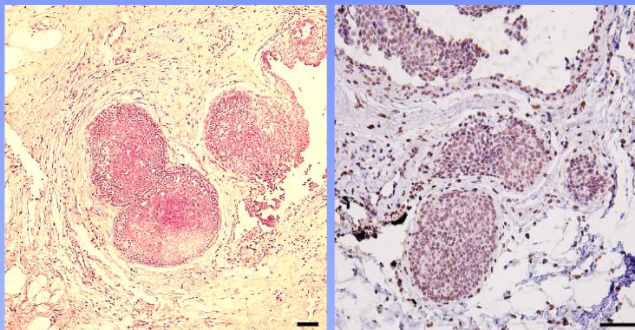
| Patient ID | Frozen on External Margins | | | | | | Permanent on External Margins | | | | | | CDP score on Internal Margins | | | | | | Permanent of CDP score sample | | | | | |
|------------|----------------------------|------|------|------|------|------|-------------------------------|------|------|------|------|------|-------------------------------|------|------|------|------|------|-------------------------------|------|------|------|------|------|
| | Inf. | Pos. | Ant. | Sup. | Med. | Lat. | Inf. | Pos. | Inf. | Sup. | Med. | Lat. | Inf. | Pos. | Ant. | Sup. | Med. | Lat. | Inf. | Pos. | Ant. | Sup. | Med. | Lat. |
| 114 | - | - | - | - | - | - | - | - | - | - | - | - | + | - | - | + | - | - | + | NS | NS | + | NS | NS |
| 115 | - | - | - | - | - | - | - | - | - | - | - | - | - | - | - | - | + | - | NS | NS | NS | NS | + | NS |
| 116 | - | - | - | - | - | - | - | - | - | - | - | - | + | - | - | - | - | - | + | NS | NS | NS | NS | NS |
| 117 | - | - | - | - | - | - | - | - | - | - | - | - | - | - | - | - | + | - | NS | NS | NS | NS | + | NS |
| 118 | - | - | - | - | - | - | - | - | - | - | - | - | - | + | - | - | - | - | NS | + | NS | NS | NS | NS |
| 119 | - | - | - | - | - | - | - | - | - | - | - | - | - | - | - | - | + | - | NS | NS | NS | NS | + | NS |
| 120 | + | - | - | - | + | - | + | - | - | - | + | - | + | - | - | - | + | - | + | NS | NS | NS | + | NS |
| 121 | - | - | + | - | - | - | - | - | + | - | - | - | - | - | + | - | - | - | + | NS | NS | + | NS | NS |
| 122 | - | - | - | - | - | - | - | - | - | - | - | - | - | - | - | - | - | - | NS | NS | NS | NS | NS | NS |
| 123 | - | - | - | - | - | + | - | - | - | - | - | + | - | - | - | - | - | + | NS | NS | NS | NS | NS | + |
| 124 | - | - | - | - | - | - | - | - | - | - | - | - | - | - | - | - | - | - | NS | NS | NS | NS | NS | NS |
| 125 | - | - | - | - | - | - | - | - | - | - | - | - | - | - | - | - | - | - | NS | NS | NS | NS | NS | NS |
| 126 | - | - | - | + | + | - | - | - | - | + | + | - | - | - | - | + | + | - | NS | NS | NS | + | + | NS |
| 127 | - | - | - | - | - | + | - | - | - | - | - | + | - | - | - | - | - | + | NS | NS | NS | NS | NS | + |
| 128 | - | - | - | - | - | - | - | - | - | - | - | - | - | - | - | - | - | - | NS | NS | NS | NS | NS | NS |
| 129 | - | - | - | - | - | - | - | - | - | - | - | - | - | - | - | - | - | - | NS | NS | NS | NS | NS | NS |
| 130 | - | - | - | - | - | - | - | - | - | - | - | - | - | - | - | - | - | - | NS | NS | NS | NS | NS | NS |
| 131 | - | - | - | - | - | - | - | - | - | - | - | - | - | - | - | - | - | - | NS | NS | NS | NS | NS | NS |
| 132 | - | - | + | - | - | - | - | + | - | - | - | - | - | - | + | - | - | - | NS | NS | + | NS | NS | NS |
| 133 | - | - | - | - | - | - | - | - | - | - | - | - | - | - | - | - | - | - | NS | NS | NS | NS | NS | NS |
| 134 | - | - | - | + | + | - | - | - | - | + | + | - | - | - | - | + | + | - | NS | NS | NS | + | + | NS |
| 135 | - | - | - | - | - | - | - | - | - | - | - | - | - | - | - | + | - | - | NS | NS | NS | - | NS | NS |
| 136 | - | - | - | - | - | - | - | - | - | - | - | - | - | - | - | - | - | + | NS | NS | NS | NS | NS | - |
| 137 | - | + | - | - | - | - | - | + | - | - | - | - | - | - | - | - | - | - | NS | NS | NS | NS | NS | NS |

Non clinical IHC on discrepancies: HIF1- alpha

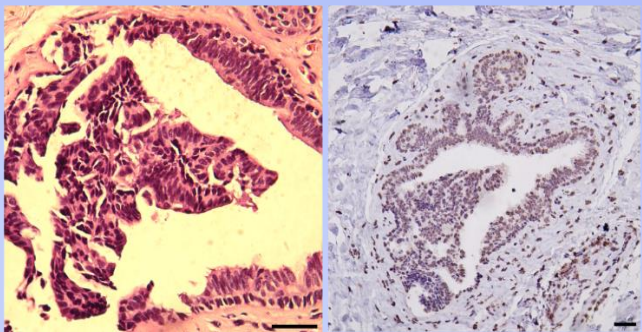
a) CDP - /Permanent (FCC with Florid ductal hyperplasia): -/ HIF -



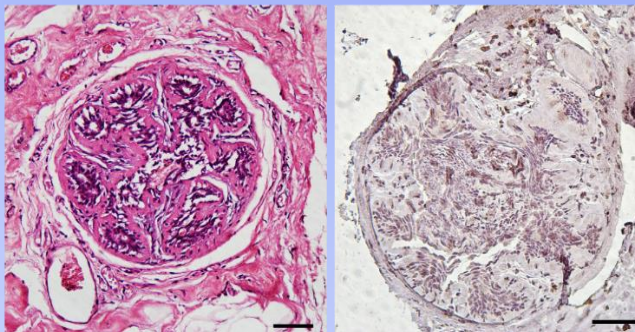
b) CDP +/Permanent (IDC grade 3): +/ HIF +



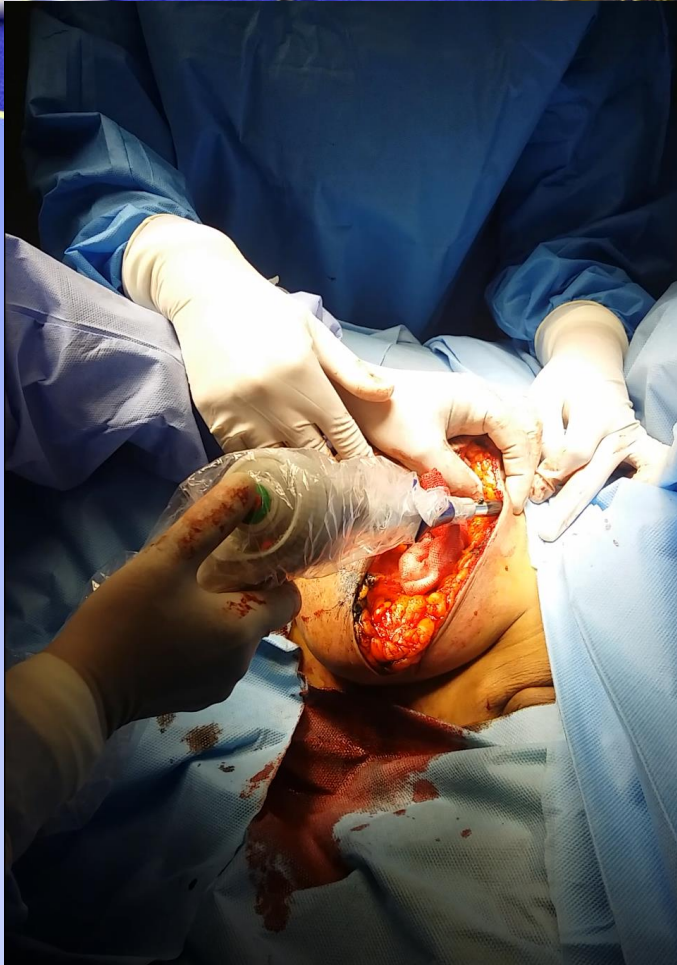c) False Positive
CDP +/Permanent (FCC): -/ HIF +



d) False Positive
CDP +/Permanent (Florid DH): -/ HIF +



New Design



My Group



Z.S. Miripour (PhD)



P. Mohaghegh (Ms.C)



P. Aghaee (Ms.C)



M. Faramarzpour (Ms.C)

My collaborators

- Dr. Abbasvandi (Surgeon)
- Prof. Kaviani (Surgeon)
- Prof. Akbari (Surgeon)
- Dr. Sadeghian (Surgeon)

- Dr. Hoseinpour (Pathologist)
- Dr. Alamdaari (Pathologist)
- Prof. Azmudeh (Pathologist)
- Dr. Kiani (Interventional Radiologist)

My collaborators



Prof. Sarkar
(Main funder)



Prof. Akbari
(SBMU, Surgeon)



Dr. Abbasvandi
(ACECR, Surgeon)



Prof. Kaviani
(TUMS, Surgeon)



Prof. Nafisi
(IUMS, Surgeon)

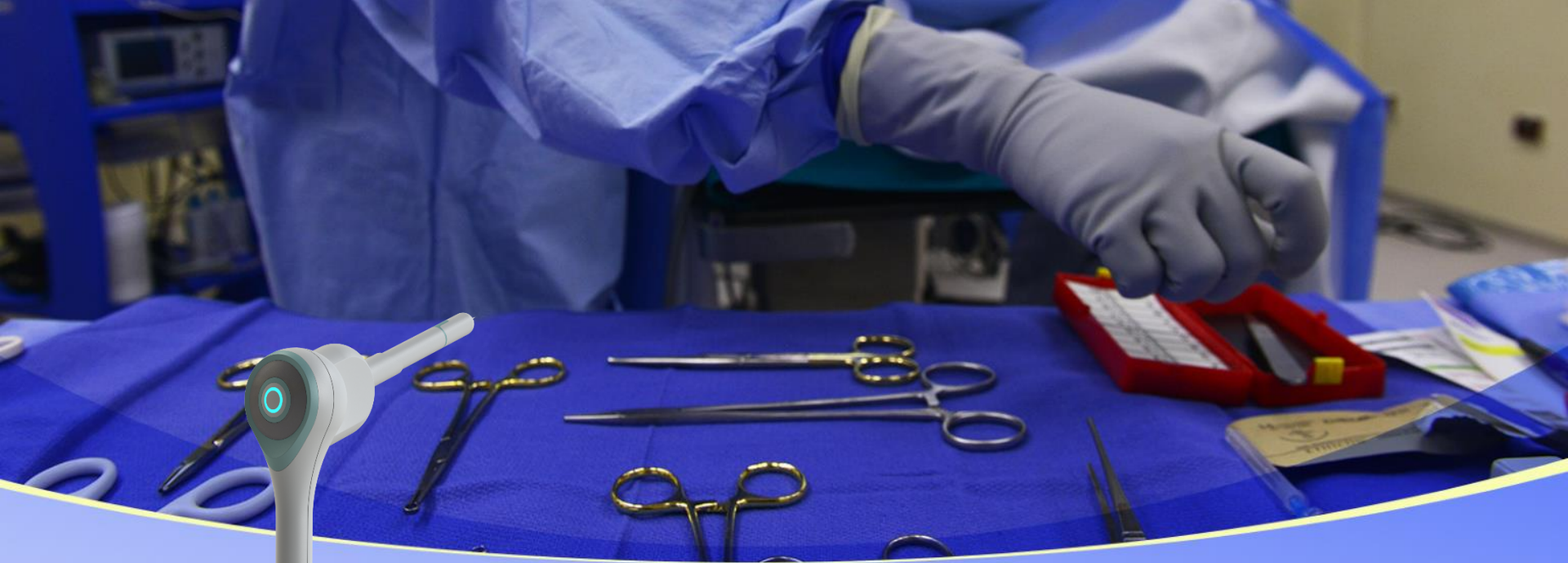Dr. Hoseinpour (Pathologist)

Dr. Alamdari (Pathologist)

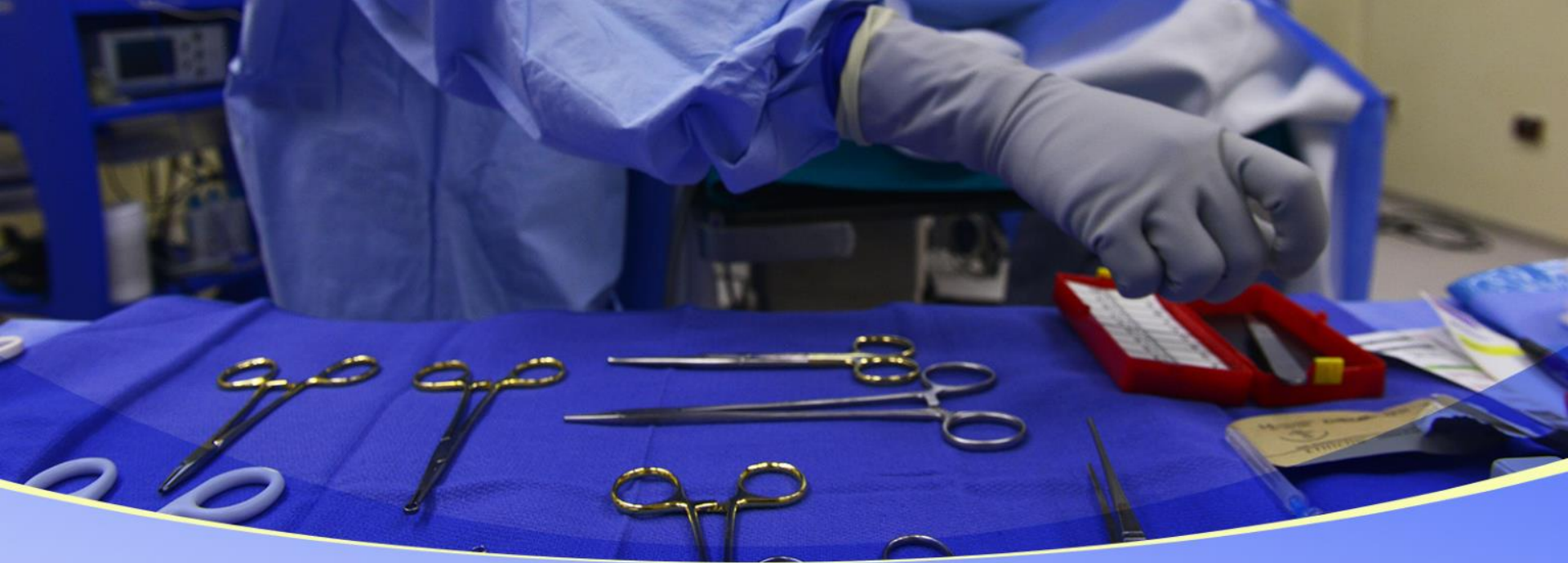Dr. Kiani (Interventional Radiologist)

Dr. Sadeghian (Surgeon)

Dr. Saravani (Surgeon)



Thanks for your Attentions



Ink Pathology

Ink Pathology

A photograph of various surgical instruments including scissors, forceps, and a scalpel, arranged on a blue surgical drape. The word "Bleeding" is written in yellow text over the top center of the image.

Bleeding

margin on CD133,

A photograph of various surgical instruments, including scissors and forceps, laid out on a blue sterile drape. The word "Poking" is written in yellow text over the center of the image.

Poking